



THE CLINICAL QUESTION

What is the diagnostic accuracy of transbronchial lung cryobiopsy (TBLC) compared with surgical lung biopsy (SLB) in undifferentiated interstitial lung disease?

TAKE HOME MESSAGE

In this multicenter prospective study, TBLC and SLB had high levels of agreement in a cohort containing predominantly interstitial pulmonary fibrosis and hypersensitivity pneumonitis/ILD.



BACKGROUND

Transbronchial lung cryobiopsy (TBLC) has emerged as a minimally invasive technique to obtain lung tissue for histopathologic analysis in the setting of undifferentiated interstitial lung disease (ILD). The lack of high-quality evidence and incompletely understood safety profile, have resulted in recent ATS/ERS/JRS/ALAT guidelines to not recommend for or against TBLC in suspected idiopathic pulmonary fibrosis cases. The issue of diagnostic accuracy of TBLC in ILD remains unresolved.

STUDY DESIGN



- Prospective, comparative, multicenter diagnostic accuracy study
- Tissue sampling was not blinded to proceduralist but blinded to pathologist review and review at MDD conference
- N: Sixty-five (65) patients, single study group (paired samples)
- Settings: Nine (9) Australian tertiary hospital with interventional pulmonology and interstitial lung disease experts
- Co-primary outcomes:
 - Agreement of histopathological features in TBLC and SLB for patterns of definite or probably usual interstitial pneumonia (UIP), indeterminate for UIP, and alternate diagnosis
 - Agreement of consensus clinical diagnosis using TBLC and SLB at MDD

POPULATION

Inclusion criteria

- Age 18-80
- Lung biopsy required for ongoing ILD care due to unclear ILD diagnosis after detailed clinical, serological, and radiological evaluation at centralized MDD meeting
- Ability to give informed consent
- No contraindications for lung biopsy

Exclusion criteria

- Hypoxemia (SpO₂ < 90%) on room air
- Diffusion capacity (DLCO) < 40% predicted
- Total lung capacity (TLC) < 50% predicted
- "Excess" bleeding risk
- Body-mass index (BMI) > 40 kg/m²
- Pulmonary hypertension, with estimated right ventricular systolic pressure > 40mmHg, or signs of right ventricular dysfunction on surface echocardiogram
- History of adverse reaction to general anesthesia
- Advanced comorbidities (including ischemic heart disease with unstable angina, current infection, uncontrolled hypertension, poorly controlled heart failure, myocarditis, severe aortic stenosis, acute pulmonary embolus, mental impairment)

Baseline Characteristics

Women 52%; mean age 66.1; mean BMI 28.8; never smoker 40%, former smoker 57%; mean FVC 83.7%, DLCO 63.4%; mean 6MWT 458m; remaining data in Table 1. No patients had pre-existing diagnosis of connective tissue disease.

OUTCOMES

Primary outcome

Agreement between TBLC and SLB was assessed using simple κ statistics. 0.61-0.80 indicated good agreement; and 0.81-1.00 indicated excellent agreement

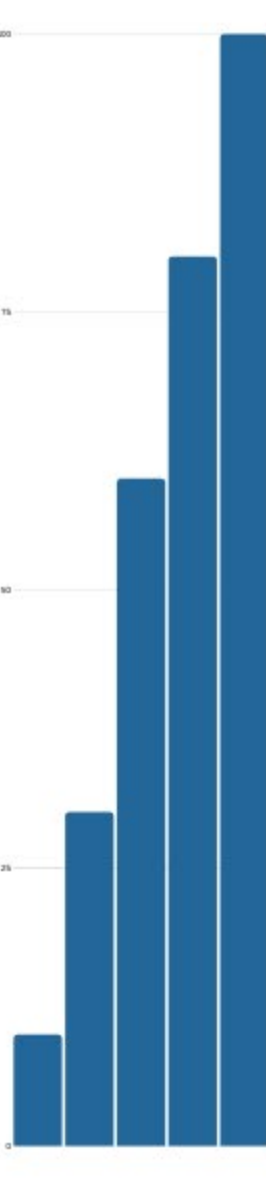
1. Agreement of histopathologic interpretation between TBLC and SLB: 70.8%, weighted κ of 0.70 (CI 0.55-0.86)
2. Agreement between final consensus clinical-radiological-pathological diagnoses for matched TBLC and SLB specimens at MDD: 76.9%, weighted κ of 0.62 (CI 0.47-0.78)

Secondary outcomes:

1. In patients with high confidence or definite TBLC diagnosis at MDD, there was concordance with SLB MDD diagnosis in 37 of 39 cases. In 26 unclassifiable or low-confidence TBLC MDD diagnosis, 6 were reclassified into alternative high confidence or definite diagnosis by SLB.
2. No difference between TBLC or SLB where biopsy led to a change in diagnostic confidence at MDD discussion ($p=0.55$)
3. No specific TBLC procedure variables (freeze time, number or size of samples, or biopsy site) were associated with agreement between TBLC and SLB
4. For histopathologic patterns, interobserver agreement between the three pathologists was, for TBLC weighted κ 0.53 (CI 0.43-0.63), for SLB weighted κ 0.64 (0.54-0.75).

Adverse events:

1. Attributed to TBLC: 14 episodes of mild-to-moderate airway bleeding; no cases of severe airway bleeding; 1 pneumothorax
2. Other: 2 ILD exacerbations
3. Overall 90-day mortality 2% (1 patient, died at 50 days from ILD exacerbation)



COMMENTARY

- This is the largest to date, prospective, multicenter study, showing good agreement between TBLC and SLB obtained sequentially for diagnosis of ILD. No major adverse events reported. Further strengthening the study, TBLC findings were reviewed without associated SLB information at MDD to limit potential bias
- Some of the limitations include: a high proportion of idiopathic pulmonary fibrosis and hypersensitivity pneumonitis (78-83%) could limit generalizability; and potential bias introduced if MDD panelists recognized presented clinical data from prior TBLC presentation when reviewing the case at MDD for SLB. Additionally, the study population excluded patients with high risk for adverse outcomes from SLB. Based on this study, the use of TBLC is not supported for patients who are marginal or not suitable for SLB
- Additional research questions include: Is TBLC as safe as SLB? (Study design here not powered to show this); and are there specific subsets of patients (eg age, comorbidities) and disease histopathology (eg IPF, NSIP, LIP) that would have equal benefit from TBLC vs SLB?

FUNDING

Investigator-initiated study with financial support from Erbe, Medtronic, Cook Medical, Rymed, Zeiss, Karl Storz, and Olympus corporations. Additional funding from the University of Sydney and John Hunter Hospital. The funders had no role in the study design, data collection, analysis, interpretation, or manuscript drafting.



SUGGESTED READING

1. DiBardino DM, Haas AR, Lanfranco AR, Litzky LA, Serman D, Bessich JL. High complication rate after introduction of transbronchial cryobiopsy into clinical practice at an academic medical center. *Ann Am Thorac Soc* 2017; 14: 851-57.
2. Sethi J, Ali MS, Mohananeey D, Nanchal R, Maldonado F, Musani A. Are transbronchial cryobiopsies ready for prime time?: a systematic review and meta-analysis. *J Bronchology Interv Pulmonol* 2019; 26: 22-32.
3. Tomassetti S, Wells AU, Costabel U, Cavazza A, Colby TV, Rossi G, et al. Bronchoscopic lung cryobiopsy increases diagnostic confidence in the multidisciplinary diagnosis of idiopathic pulmonary fibrosis. *Am J Respir Crit Care Med*. 2016;193:745-752.

ARTICLE CITATION



Troy LK, Grainge C, Corte TJ, Williamson JP, Valley MP, Cooper WA, Mahar A, Myers JL, Lai S, Mulyadi E, Torzillo PJ, Phillips MJ, Jo HE, Webster SE, Lin QT, Rhodes JE, Salamons M, Wrobel JP, Harris B, Don G, Wu P, Ng NJ, Oldmeadow C, Raghu G, Lau E (2019). "Diagnostic accuracy of transbronchial lung cryobiopsy for interstitial lung disease diagnosis (COLDICE): a prospective, comparative study". *Lancet Respir Med*. doi: 10.1016/S2213-2600(19)30342-X. [Epub ahead of print]